Twelve Nerves, Twelve Small Requests

the whole examination is made of gestures — smile, clench, shrug, say ah — and every one of them is compared left against right.

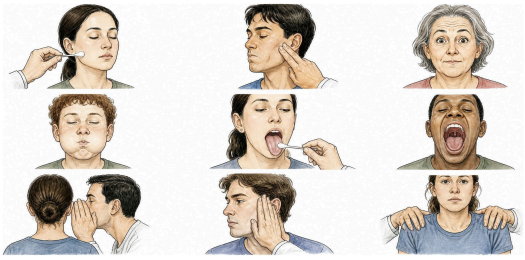

What you ask for, and what it tests

SKILLS 6.5

Twelve nerves: three strictly sensory, five strictly motor, four mixed.



I OLFACTORY · II OPTIC

Identify an odour, eyes closed · Snellen at 20 feet

Loss of smell is **anosmia**. Near vision: card at **14 inches**. **20/40 means they see at 20 feet what normal vision sees at 40** — bigger denominator, worse vision. Glasses worn: document as **corrected vision**.



III · IV · VI

Oculomotor, trochlear, abducens — tested as one manoeuvre

PERRLA and the cardinal fields. Deficits present as **diplopia**, **ptosis**, and an inability to move the eyes in a given direction.



V TRIGEMINAL · VII FACIAL

Cotton wisp to the face · clench the teeth · smile, puff, frown, raise the brows

V motor: palpate **temporalis and masseter** while they clench. VII sensory: taste — **salt, sugar, lemon** on separate swabs to the **anterior tongue**. Deficits: absent corneal reflex; **facial droop**.



VIII VESTIBULOCOCHLEAR

Whispered voice test, and Romberg

Hears whispered words in both ears; stands upright and keeps balance.



IX GLOSSOPHARYNGEAL · X VAGUS

Say "ah" · touch the posterior pharynx

Uvula and tongue **midline**, uvula rises **symmetrically**, **gag reflex present**; then gag **followed by a swallow**. **The two work together for the integration of gag and swallowing** — which is why a deficit in either is a swallowing-safety finding.



XI ACCESSORY · XII HYPOGLOSSAL

Spinal accessory: turn the head against resistance and shrug · hypoglossal: protrude the tongue

XI is **both** the sternocleidomastoid and the trapezius — inspect for **winging of the scapula** and shoulder drooping before applying resistance. XII: with unilateral weakness the tongue **points to the affected side**, from the unopposed action of the normal muscle.

Both mnemonics are in the source: *"On Old Olympus Towering Tops A Finn And German Viewed Some Hops"* and *"Oh Once One Takes The Anatomy Final Very Good Vacations Are Heavenly."*
And a flagged defect: Table 6.5 assigns **ptosis** and the inability to look **up, down, inward, outward or diagonally** to the **trochlear** row. Ptosis is an eyelid finding and the full-range deficit describes oculomotor territory; the trochlear nerve controls a single extraocular muscle. Reproduced here as the composite III/IV/VI finding a nurse documents — but not to be learned as anatomy.